Repair of Reverse Conical AAA with an ALTO Endograft

Emily Rey, DO; Roople Risam, MD; Edwin Acosta, MD; Kristian Hochberg, MD

ArnotHealth Arnot Ogden Medical Center, Diagnostic Radiology Department, Elmira, NY

LECOMT LAKE ERIE CONSORTIUM FOR OSTEOPATHIC MEDICAL TRAINING

BACKGROUND

A 67 year old male presented to the Emergency Department for abdominal pain that had worsened over the past few days. Computerized tomography (CT) of the abdomen, performed at the time of his presentation, showed a fusiform aneurysm of the distal abdominal aorta measuring 6.9 cm in greatest diameter. His symptomatic, large abdominal aortic aneurysm (AAA) was noted to have "hostile" anatomy on computed tomography angiography (CTA). Specifically, it had a "reverse conical neck". Abdominal endovascular aneurysm repair (EVAR) was subsequently performed with 34 mm ALTO endograft, achieving exclusion of the AAA without compromising the renal arteries.

Figure 1

Figure 2

IMAGING

Coronal reformation from a CTA of the Chest, Abdomen and Pelvis (**Figure 1**) demonstrates the "reverse conical" configuration of the aortic neck of the infrarenal aneurysm (red lines).

Digital Subtraction Angiography (DSA) (**Figure 2**) shows the reverse conical morphology of the aortic neck.

Subsequent DSA at the conclusion of the procedure (**Figure 3**) showed excellent placement of the ALTO endograft with flow preserved within bilateral renal arteries. No evidence of endoleak was seen on contrast-enhanced ultrasound performed at three month follow-up (**Figure 4**).

DISCUSSION

Symptomatology that is attributable to an AAA should elicit prompt consideration of repair. Increasing diameter is also associated with risk of aneurysm rupture. Specifically, the Joint Council of the American Association for Vascular Surgery and Society for Vascular Surgery published estimates of annual risk according to the diameter in centimeters, with 4.0 to 4.9 associated with 0.5% to 5% risk, 5.0 to 5.9 associated with 3% to 15%, and 6.0 to 6.9 associated with 10% to 20%.

Analysis of abdominal arterial morphology and features is of the utmost importance in the pre-procedural planning of EVAR, as certain features may constitute "hostile" anatomy. One of the most hostile features is termed the "reverse conical neck", which is generally defined as an aortic diameter increasing approximately 2-4 mm over a span of 10 mm below the level of the renal arteries.

DISCUSSION (cont.)

However, even in the setting of such hostile features, designing effective solutions based on the operator's expertise may allow for percutaneous intervention in those otherwise unable to undergo open repair and allow the patient to benefit from the reduced periprocedural mortality and morbidity of EVAR compared to an open surgical approach.

Historically, such work-arounds included branched or fenestrated grafts that effectively raised the proximal seal zone to above the renal arteries. These grafts would take weeks to build, precluding their use in many urgent or emergent cases. Infrarenal fixation devices such as the AFX endograft have been utilized for several years, which allow for greater conformation to the hostile aortic anatomy. Very recently, the ALTO endograft design has introduced an adaptive sealing via a unique, conformable liquid polymer that permits an even greater theoretical seal. Given their novelty, as very few have been deployed in general at this point, their efficacy for treating hostile anatomy can provide an avenue for treatment that can improve outcomes in patients who would otherwise undergo more difficult percutaneous or open repair.

Figure 3

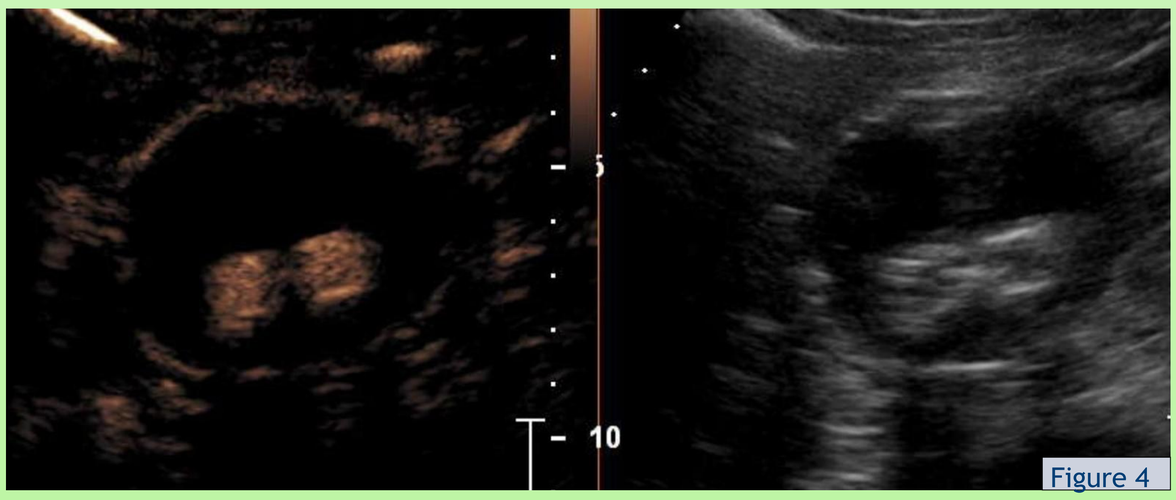

Figure 4

REFERENCES

1. Bryce Y, Rogoff P, Romanelli D, Reichle R. Endovascular repair of abdominal aortic aneurysms: vascular anatomy, device selection, procedure, and procedure-specific complications. Radiographics. 2015;35(2):593-615. doi:10.1148/rg.352140045
2. Lee JH, Park KH. Endovascular Aneurysm Repair in Patients with Conical Neck Anatomy. Vasc Specialist Int. 2017;33(2):59-64. doi:10.5758/vsi.2017.33.2.59
3. Pitoulias GA, Valdivia AR, Hahtapornsawan S, et al. Conical neck is strongly associated with proximal failure in standard endovascular aneurysm repair. J Vasc Surg. 2017;66(6):1686-1695. doi:10.1016/j.jvs.2017.03.440

CONTACT

Emily Rey, DO: erey@arnothealth.org
Roople Risam, MD: roople.risam@arnothealth.org