Thrombin Injection for Traumatic Pseudoaneurysm

Emily Rey, DO; Roople Risam, MD; Edwin Acosta, MD; Kristian Hochberg, MD

ArnotHealth Arnot Ogden Medical Center, Diagnostic Radiology Department, Elmira, NY

LECOMT LAKE ERIE CONSORTIUM FOR OSTEOPATHIC MEDICAL TRAINING

BACKGROUND

A 69 year old patient presented, from a rehab facility after femoral open reduction and internal fixation surgery, to the Emergency Department for left lower leg swelling. Patient stated that a nurse at her facility had rested her arm on her leg during a blood draw and immediately afterward the patient began to notice swelling. A complex hematoma with fluid-fluid levels in the region was found on computed tomography angiography (CTA). Her scheduled dose of rivaroxaban, an anticoagulant, was held, and she was given prothrombin complex concentrate for elevated coagulation laboratory values. Subsequent ultrasound (US) evaluation by the interventional radiologist demonstrated to and fro Doppler signal involving two locations at the margin of the hematoma characteristic of pseudoaneurysms. These pseudoaneurysms were implicated as the cause of her expanding hematoma, and US guided thrombin was injected into these sites. The previously noted Doppler flow ceased after treatment, and she was placed in a foot-to-knee compression, three layer compression. Follow-up US the next day showed no expansion or evidence of flow into the hematoma.

Figure 1

IMAGING

CTA of the left lower extremity soft tissues showed a large, heterogeneous collection adjacent to the proximal to mid tibia, extending from the cutaneous layer to the deep subcutaneous fat compatible with subacute hematoma (**Figure 1**).

Duplex US (**Figure 2**) showed two foci of Color Doppler to and fro flow compatible with pseudoaneurysms at the upper margin of a complex appearing hematoma (red arrow indicates one of these sites). After skin preparation and anesthesia, a 22-gauge spinal needle was inserted under real-time US with needle tip placed at the site of visible pseudoaneurysms (**Figure 3**). Thrombin was injected into both sites, with the total amount utilized being 3000 units. There was absence of visible pseudoaneurysm after the injections.

DISCUSSION

A pseudoaneurysm has a saccular shape and is associated with a greater risk of rupture compared to “true” aneurysms. Typically, they are seen after endovascular intervention involving wire and catheter manipulation within an arterial lumen, most commonly in the groin. On imaging, they have a characteristic to and fro flow pattern on Color Doppler US that is sometimes referred to as a “Ying-Yang Sign.” Treatment includes exclusion of the lesion with a covered stent, ultrasound probe compression of the pseudoaneurysm neck to cause thrombosis of the pseudoaneurysm, surgical ligation, and ultrasound-guided thrombin injection.

Reducing the risks of an intervention while maximizing success rates is often a difficult balance. Catheter-based and surgical interventions carry increased risk of vessel wall injury and are generally more traumatic to the patient. Using only compression at the neck of the pseudoaneurysm has limited success, especially with patients who are taking anticoagulants and antiplatelets, which unfortunately includes the vast majority of the patient pool.

Ultrasound-guided thrombin (aka Factor IIa) injection is a technique that utilizes the conversion of fibrinogen into fibrin directed into the pseudoaneurysm, causing it to clot off. It is abundantly cited as an effective treatment and often the treatment of choice for iatrogenic groin pseudoaneurysms. Non-groin pseudoaneurysms and non-iatrogenic pseudoaneurysms are encountered infrequently, and the utility of this technique for these kinds of pseudoaneurysms is not well researched. However, this technique proved effective in the aforementioned patient without necessitating the need for more invasive treatment.

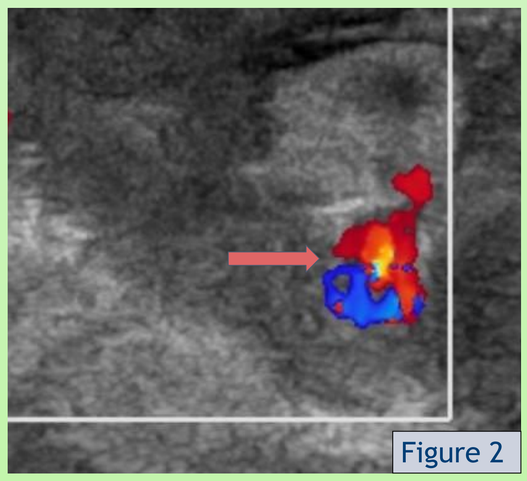

Figure 2



Figure 3

REFERENCES

1. Cope C, Zeit R. Coagulation of aneurysms by direct percutaneous thrombin injection. AJR Am J Roentgenol. 1986;147(2):383-387. doi:10.2214/ajr.147.2.383
2. Friedman SG, Pellerito JS, Scher L, Faust G, Burke B, Safa T. Ultrasound-guided thrombin injection is the treatment of choice for femoral pseudoaneurysms. Arch Surg. 2002;137(4):462-464. doi:10.1001/archsurg.137.4.462
3. Olsen DM, Rodriguez JA, Vranic M, Ramaiah V, Ravi R, Diethrich EB. A prospective study of ultrasound scan-guided thrombin injection of femoral pseudoaneurysm: a trend toward minimal medication. J Vasc Surg. 2002;36(4):779-782.
4. Valesano JC, Schmitz JJ, Kurup AN, et al. Outcomes of Ultrasound-Guided Thrombin Injection of Nongroin Arterial Pseudoaneurysms. J Vasc Interv Radiol. 2017;28(8):1156-1160. doi:10.1016/j.jvir.2017.05.003

CONTACT

Emily Rey, DO: erey@arnothealth.org

Roople Risam, MD: roople.risam@arnothealth.org