ArnotHealth
Graduate Medical Education

A Case Report on Drug Induced Hepatotoxicity

Sadaf Mughal, MD, Muhammad Sarfraz, MD, Maarya Bokhari, MD, Ben Allison, MD, Abdelkader Mallouk, MD, Xiaoyan Liao, MD/PhD

Timothy Baxter, MD, Department of Family Medicine, Arnot Ogden Medical Center, Elmira, NY

LECOMT
LAKE ERIE CONSORTIUM FOR OSTEOPATHIC MEDICAL TRAINING

Case Presentation:

- 63 year old female with history of Ulcerative Colitis diagnosed in 2018 with complaints of Jaundice, abdominal pain, fatigue, nausea, vomiting, dark color urine and light color stool of two weeks in duration.
- This visit was telemedicine due to COVID-19 pandemic, no physical examination performed.
- Liver Panel was significant for Albumin 2.2 g/dl, Alkaline phosphatase 146 units/l, Total bilirubin 30.5mg/dl, Conjugated bilirubin 18.5 mg/dl, Unconjugated bilirubin 12.0 mg/dl, AST 293 Units/L, ALT 285 Units/L, GGTP 228 Units/L, LDH 246 IU/L. CBC significant for RBC counts 3.12 10 x 6/ul, MCV 116 FL, MCH 39.7 PG , RDW 26.1%. BMP significant for Sodium 134 mMOL/L, Potassium 3.2 m MOL/L, Chloride 99 m MOL/L, Calcium 8.1 MG/DL.
- Ultrasound abdominal showed surgical absent gall bladder otherwise unremarkable.
- Referred to Hepatologist for suspected drug induced hepatotoxicity and discontinued mercaptopurine.
- Liver biopsy shows diffuse canalicular and hepatocytic cholestasis accompanied with hepatocyte swollen degeneration, foci of drop out (bile infarct), mild portal and lobular inflammation (A-C). Trichrome stain (D) reveals no significant fibrosis

Follow up Visits:

- Patient started on Apriso (mesalamine) capsule extended release 24 hours 0.375 GM 4 capsule orally once a day.
- Regular follow up showed resolution of ulcerative symptoms, CBC, CMP and Liver panel continue to trend down normal except alkaline phosphatase which persistently elevated 145 Units/L but trend down to 138 on next visit.
- Plan is to follow up patient for Ulcerative Colitis symptoms and monitor Alkaline phosphatase for complete resolution of Mercaptopurine induced hepatoxicity.

Time of diagnosis
- Started on Entocort (Budesonide) delayed release 2 capsules orally every morning
- Pentasa (Mesalamine) 500 mg extended release take 2 capsules by mouth 4 times a day.

1 month follow up
- Diarrhea improved, occasional blood in stool, No abdominal cramp
- Continued Entocort and Pentasa

2 months follow up
- Stool now soft and formed
- Continued Urgency and Blood in Stool
- Stopped Entocort and Pentasa
- Started on started on Uceris (budesonide) tablet extended release 9mg 1 tablet QD and Apriso (mesalamine) capsule extended release 24 hours 0.375 GM 4 capsule orally once a day

3 months follow up visit
- Patient complaint return of abdominal pain, cramping, diarrhea and blood in stools similar to prior treatment. Started on Humira (Adalimumab) 40 mg /0.8ml subcutaneous injection once a week.
- On Humira, symptoms got better but not resolved completely,
- Added Mercaptopurine 50mg 1 tablet orally for 2 weeks then 2 tablet daily to Humira.

- After approximately 4 months of starting Mercaptopurine, patient started having Jaundice, abdominal pain, fatigue, nausea, vomiting, dark color urine and light color stool.

1 month follow up
- Occasional abdominal cramps , decrease frequency of diarrhea and Blood in stool
- Continued Apriso and Uceris

- 20 days later, patient came with increase diarrhea frequency and blood in stool
- Stop Apriso
- Continued Uceris

- 15 days later, patient came with diffuse abdominal pain with cramping
- Increase diarrhea frequency
- Increase blood in stool
- Started on Prednisone 10 mg 2 tablets orally twice a day and Bactrim DS tablet , orally twice a day

2 weeks follow up
- Symptoms improved
- Restart on Apriso
- Taper on prednisone.

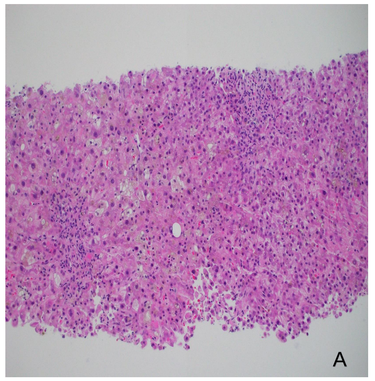

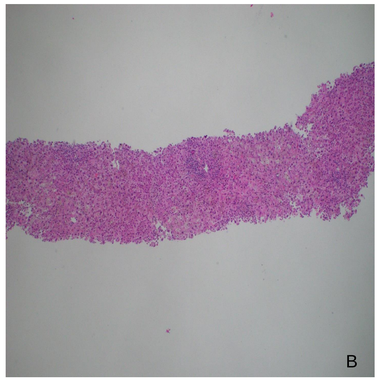

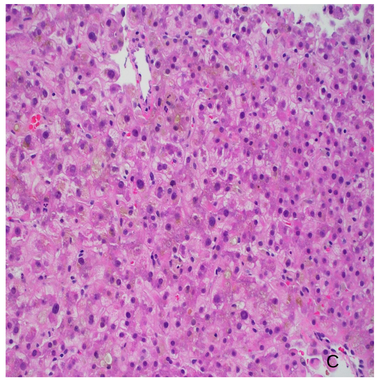

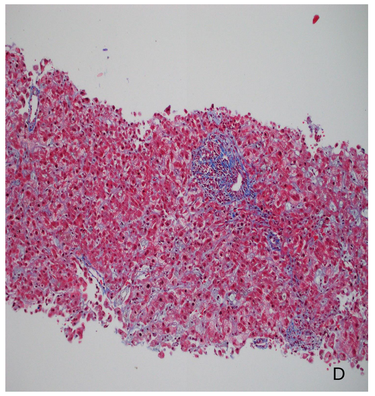

- Liver biopsy shows diffuse canalicular and hepatocytic cholestasis accompanied with hepatocyte swollen degeneration, foci of drop out (bile infarct), mild portal and lobular inflammation (A-C). Trichrome stain (D) reveals no significant fibrosis

Discussion

- Drug hepatoxicity can be nonidiosyncratic or idiosyncratic. New epidemiologic data suggest that approximately 20 new cases of DILI (drug- induced liver injury) per 100,000 persons occur each year. Idiosyncratic DILI accounts for 11% of the cases of acute liver failure in the United States.[1]
- The antimetabolite mercaptopurine is commonly used as treatment for inflammatory bowel diseases.[2]
- 6-MP induced hepatotoxicity is uncommon in the adult population and associated with the 6-MP metabolite 6-methylmercaptopurine ribonucleotide (6-MMPR), hepatotoxicity is associated with higher mean 6-MMPR levels.
- The Monitoring liver tests in patients on 6-MP is suggested, and dose reduction or cessation of 6-MP.[3]

References

1. DrLeise MD, Poterucha JJ, Talwalkar JA. Drug-induced liver injury. *Mayo Clin Proc*. 2014;89(1):95-106. doi:10.1016/j.mayocp.2013.09.016
2. Chen LJ, Nightingale G, Baer MR. Mercaptopurine-induced fever: hypersensitivity reaction in a patient with acute lymphoblastic leukemia. *Pharmacotherapy*. 2010;30(1):113. doi:10.1592/phco.30.1.113
3. Shaye OA, Yadegari M, Abreu MT, et al. Hepatotoxicity of 6-mercaptopurine (6-MP) and Azathioprine (AZA) in adult IBD patients. *Am J Gastroenterol*. 2007;102(11):2488-2494. doi:10.1111/j.1572-0241.2007.01515

For additional information please contact:
Sadaf Mughal MD; sadaf.mughal@arnothealth.org