PRES Syndrome versus Bilateral Posterior Infarcts: A Difficult Distinction

Emily Rey, DO; David Rayne, MD; Roople Risam, MD; David Chung, MD

ArnotHealth Arnot Ogden Medical Center, Diagnostic Radiology Department, Elmira, NY

LECOMT LAKE ERIE CONSORTIUM FOR OSTEOPATHIC MEDICAL TRAINING

BACKGROUND

An 86 year old male presented to the Emergency Department (ED) after falling when attempting to get out of bed that morning. On presentation, he had bilateral blurred vision and transient left hand weakness. He was noted to have new onset atrial fibrillation (Afib) with rapid ventricular rate in the ED. No large vessel occlusion was seen on computed tomography angiography (CTA), but magnetic resonance imaging (MRI) suggested bilateral occipital infarcts. He was managed medically for his Afib and worked with Occupational Therapy. While his central vision improved, his loss of peripheral vision persisted.

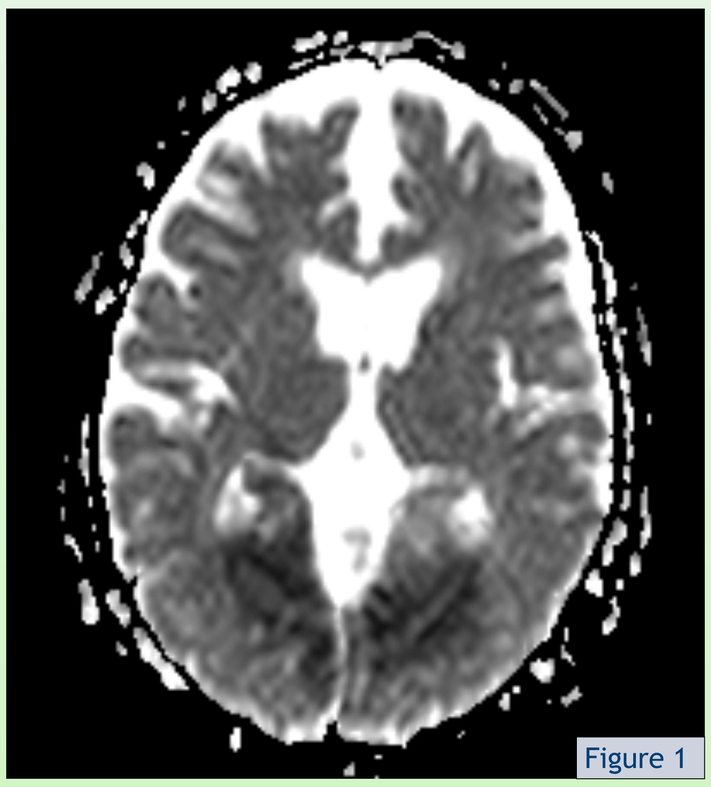

Figure 1

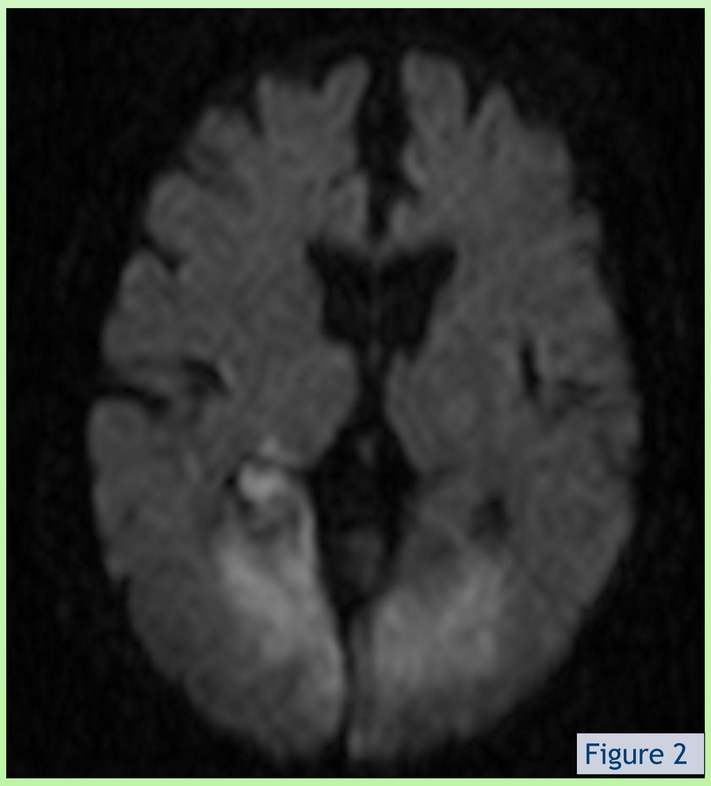

Figure 2

IMAGING

MRI of the Brain demonstrated symmetric appearing regions of restricted diffusion within each posterior temporal and occipital lobe, particularly involving the region of the visual cortices. This is represented by hypointensity on apparent diffusion coefficient (ADC) (**Figure 1**) and hyperintensity of diffusion-weighted imaging (DWI) (**Figure 2**). These imaging characteristics can be compatible with bilateral posterior circulation infarcts or posterior reversible encephalopathy.

3D rendering from CTA of the Brain (**Figure 3**) showed no large vessel occlusions.

DISCUSSION

Posterior Reversible Encephalopathy Syndrome (PRES) is caused by a multitude of factors, the most common of which include hypertension, preeclampsia, renal failure, sepsis, thrombocytopenia, alcohol withdrawal, and the administration of cytotoxic or immunosuppressive medications. Its pathophysiology is not entirely understood, although the fundamental mechanism is dysregulation of vascular tone. It also has a multitude of patterns on MRI, but the most common (seen in 70%) is parieto-occipital vasogenic edema because of the sensitivity of the posterior circulation to changes in blood pressure. Patients with this condition can present with confusion, headache, or with a number of nonspecific neurologic complaints. When involving the occipital lobe, symptoms often include changes or loss of vision and can even result in blindness. Restricted diffusion is atypical, but can occur in approximately 17% of cases.

Bilateral occipital lobe infarction is rare, and often prompted by embolism affecting the vertebrobasilar system. Typically, patients have a history of atherosclerosis and are advanced in age. Embolic risk factors such as elevated CHA2DS2-VASc score with Afib can also elevate suspicion of infarct. Both infarct and PRES benefit from close regulation of blood pressure.

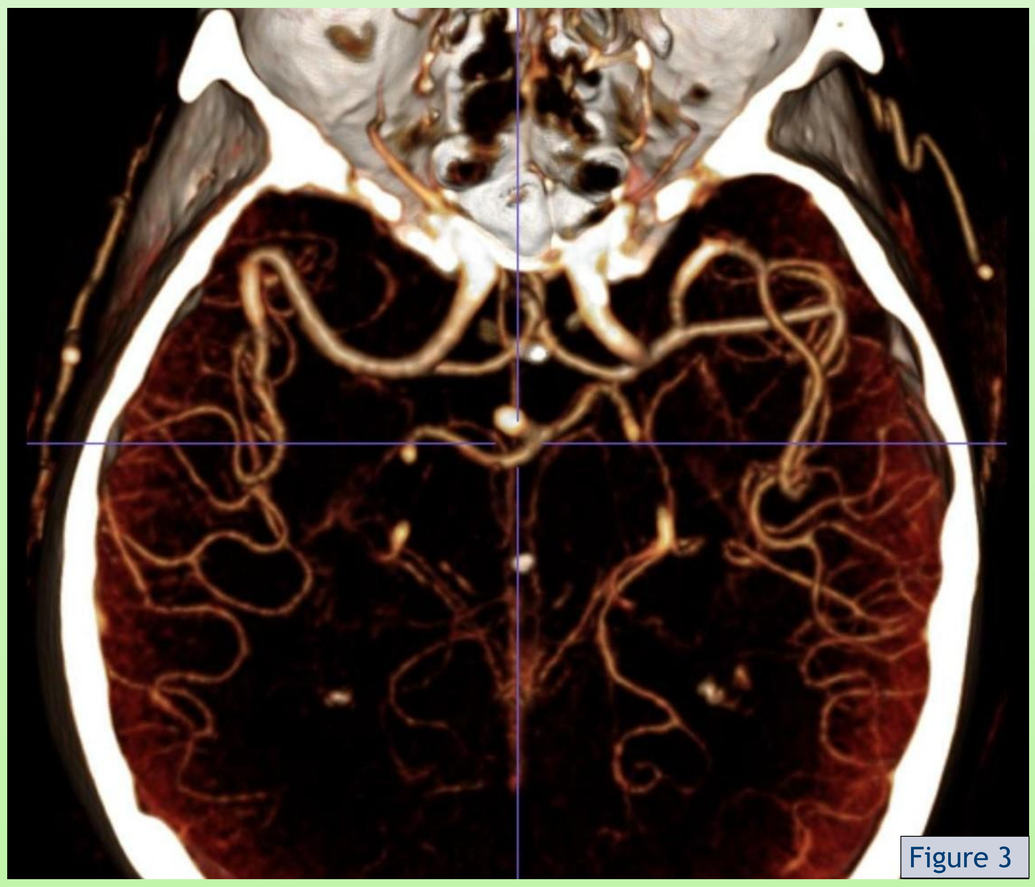

Figure 3

REFERENCES

1. Bartynski WS, Boardman JF. Distinct imaging patterns and lesion distribution in posterior reversible encephalopathy syndrome. AJNR Am J Neuroradiol. 2007;28(7):1320-1327. doi:10.3174/ajnr.A0549
2. Fugate JE, Rabinstein AA. Posterior reversible encephalopathy syndrome: clinical and radiological manifestations, pathophysiology, and outstanding questions [published correction appears in Lancet Neurol. 2015 Sep;14(9):874]. Lancet Neurol. 2015;14(9):914-925. doi:10.1016/S1474-4422(15)00111-8
3. McKinney AM, Short J, Truwit CL, et al. Posterior reversible encephalopathy syndrome: incidence of atypical regions of involvement and imaging findings. AJR Am J Roentgenol. 2007;189(4):904-912. doi:10.2214/AJR.07.2024
4. Satija L, Singh AP, Khanna SK, Baijal V, Verma BS. RARE CAUSE OF COMPLETE BLINDNESS : BILATERAL OCCIPITAL CORTICAL INFARCTION: A Report on Three Cases. Med J Armed Forces India. 1999;55(2):149-150. doi:10.1016/S0377-1237(17)30273-3

CONTACT

Emily Rey, DO: erey@arnothealth.org

Roople Risam, MD: roople.risam@arnothealth.org