Contrast-Enhanced Ultrasound as a Novel Alternative in the Detection and Characterization of Endoleaks Post-EVAR

Emily Rey, DO; Roople Risam, MD; Edwin Acosta, MD; Kristian Hochberg, MD

ArnotHealth Arnot Ogden Medical Center, Diagnostic Radiology Department, Elmira, NY

LECOMT LAKE ERIE CONSORTIUM FOR OSTEOPATHIC MEDICAL TRAINING

PURPOSE

There is a large prevalence of cardiovascular disease such as Abdominal Aortic Aneurysm requiring Endovascular Aneurysm Repair (EVAR) in patients with chronic kidney disease. These patients would benefit from radiologic evaluation that would preclude the need for renally excreted contrast. Often, patients with underlying renal disease undergo monitoring with serial non-contrast Computed Tomography (CT) or non-contrast Ultrasound (US), which provides information on only the overall size of the aneurysm sac and does not demonstrate the presence of an endoleak, its type, or its location. Contrast-Enhanced Ultrasound (CEUS) could be used as a primary or complementary modality for endoleak detection or surveillance as CEUS is primarily excreted by the lungs, not the kidneys.

CEUS removes the negative effects of radiation exposure and potentially nephrotoxic iodinated contrast from the process of endoleak evaluation. The goal of this study is to provide objective data supporting the use of CEUS as an alternative to CT angiogram (CTA) and non-enhanced US.

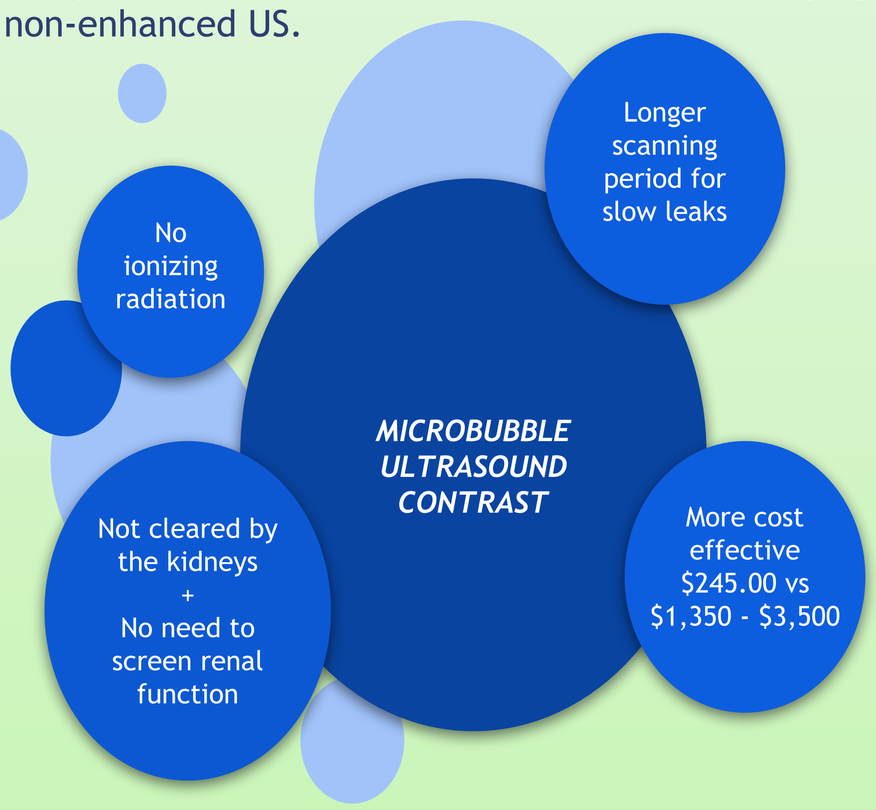

METHODS

This is a prospective study with an anticipated sample size of 50 patients. CEUS will be performed, evaluating the abdominal aorta post-EVAR with particular focus on endoleak characterization, as an adjunct examination on the same day as the current standard of diagnostic imaging after EVAR, which includes CTA and non-contrast US. Adult patients who are post-EVAR obtaining CTA or non-contrast US for surveillance and endoleak detection after EVAR without history of reaction to venous administration of US microbubble contrast will be included in the study.

RESULTS

Due to the COVID-19 pandemic, this IRB approved and grant funded research initiative remains in progress. Preliminary data indicates a greater sensitivity in CEUS compared to CTA and non-contrast US in the detection and characterization of endoleaks, particularly Type II endoleaks. Of the patients sampled, a Type II endoleak was detected by CTA on a single patient. CEUS detected two Type II endoleaks, with one not seen on the previous CTA corresponding to that patient. In the case of the Type II endoleak seen on CTA, the corresponding CEUS was able to characterize the origin of the Type II endoleak and also suggested a Type IIIa endoleak not detected on the previous CTA. Of the remaining cases, CEUS resulted in similar findings regarding endograft and endoleak characterization as compared to CTA.

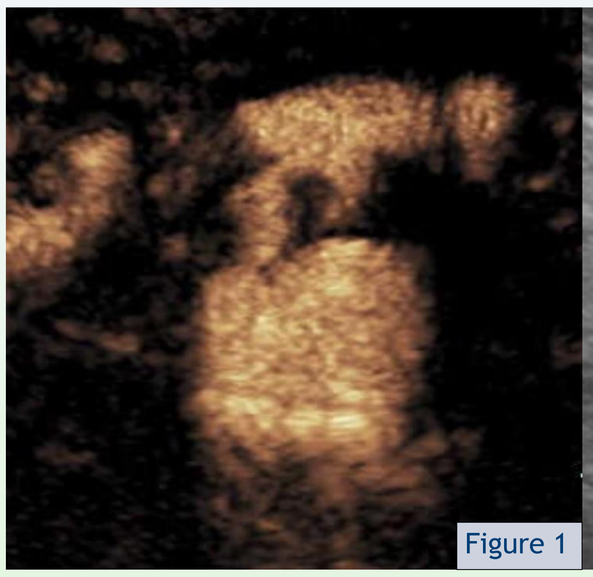
Figure 1

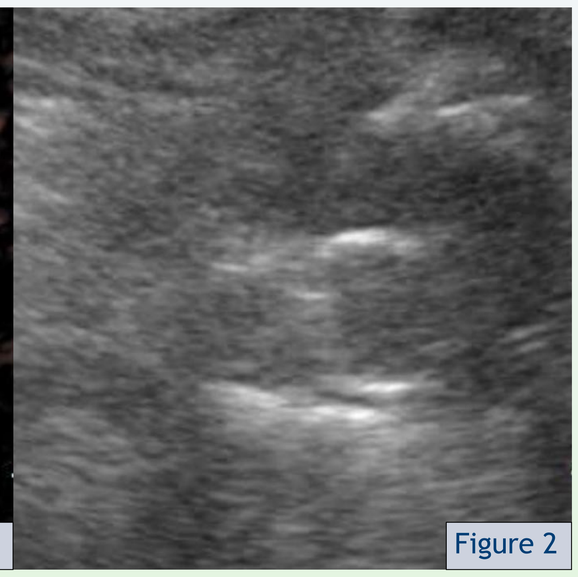
Figure 2

Injection of microbubble contrast (**Figure 1**) demonstrates initial normal enhancement of the aorta and both iliac limbs. Subsequently, there was microbubble enhancement noted within the aneurysmal sac anterior to the left iliac limb of the graft, 11 seconds after contrast injection, suggestive of Type IIIa endoleak involving the left iliac limb. The ability to scan continuously over a period of time is a notable advantage of CEUS.

Noncontrast grayscale image obtained simultaneously (**Figure 2**) shows no visible abnormality.

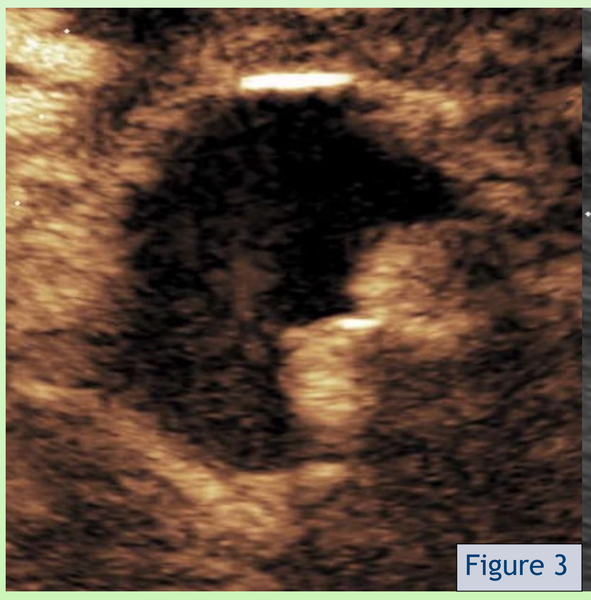
Figure 3

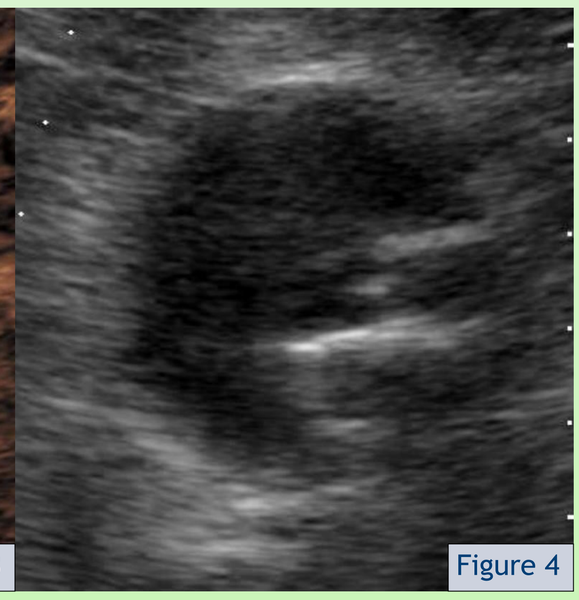
Figure 4

Injection of microbubble contrast demonstrates normal enhancement of the aorta and bilateral limbs without evidence of endoleak (**Figure 3**).

Concurrent grayscale imaging shows that the aortic graft has unremarkable grayscale appearance and flow (**Figure 4**).

REFERENCES

1. Cury MH, Cury MV, Godoy MR, Matielo MF. Advantages of contrast-enhanced ultrasonography over computed tomography for the detection of persistent type II endoleak after embolization: A case report. J Clin Ultrasound. 2016;44(8):522-526. doi:10.1002/jcu.22356
2. Gürtler VM, Sommer WH, Meimarakis G, et al. A comparison between contrast-enhanced ultrasound imaging and multislice computed tomography in detecting and classifying endoleaks in the follow-up after endovascular aneurysm repair. J Vasc Surg. 2013;58(2):340-345
3. Harky A, Zywicka E, Santoro G, Jullian L, Joshi M, Dimitri S. Is contrast-enhanced ultrasound (CEUS) superior to computed tomography angiography (CTA) in detection of endoleaks in post-EVAR patients? A systematic review and meta-analysis. J Ultrasound. 2019;22(1):65-75. doi:10.1007/s40477-019-00364-7
4. Malone CD, Fetzer DT, Monsky WL, et al. Contrast-enhanced US for the Interventional Radiologist: Current and Emerging Applications. Radiographics. 2020;40(2):562-588. doi:10.1148/rg.2020190183

CONTACT

Emily Rey, DO: erey@arnothealth.org
Roople Risam, MD: roople.risam@arnothealth.org